

Wolf Teeth

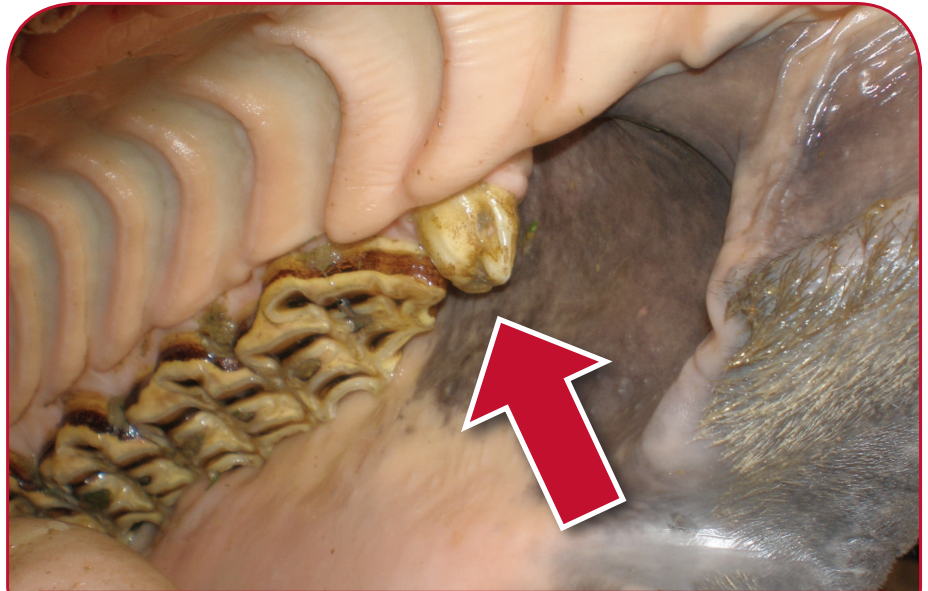
What are Wolf Teeth?

Wolf teeth are small peg-like teeth that sit just in front of the first cheek teeth of horses. They have no function and if present are normally found in the maxilla (upper jaw), although mandibular (lower jaw) wolf teeth are found very occasionally.

They are often shed when the first cheek tooth cap is shed at around two and a half years of age. They may sometimes also be knocked out by the bit or when routine equine dentistry is performed. They are extremely variable in size from being small pegs only a few millimetres in diameter to having roots up to two centimetres long.

Studies suggest that they normally erupt between birth and 18 months.

It is impossible to gauge the size of the root from an examination of the crown, except to say that if the crown is mobile it is very unlikely that there is a large intact root.



A LARGE WOLF TOOTH

Removal of Wolf Teeth

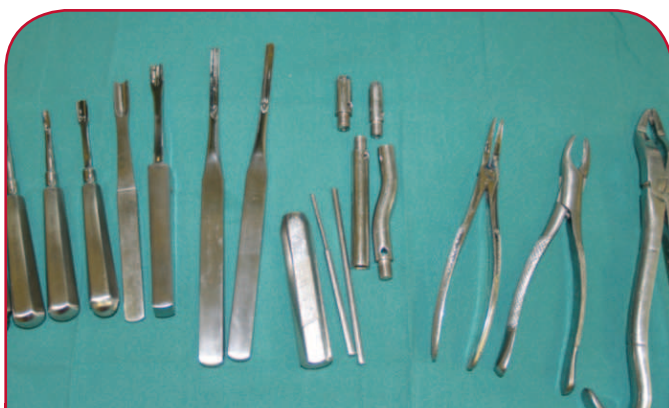Wolf teeth should be removed under sedation and ideally local anaesthetic. It is essential that the whole tooth including the root is removed and that minimal gum trauma caused. Use of a headstand and adequate

light are essential to ensure safe and complete removal of the tooth.

Wolf teeth can be removed using a variety of instruments. These are used to cut the ligament that attaches the tooth to the underlying tissue. Once loose the tooth can be grasped with forceps and extracted.

Some wolf teeth may be displaced and may sit below the gum line, often lying at an angle. These wolf teeth are called 'blind' wolf teeth. These are identified by careful examination on the area of the gum in front of the cheek teeth. Removal of the 'blind' teeth requires an incision of the gum prior to extraction.

After removal, horses should be given tetanus antitoxin (if not vaccinated) and a period of time off work without a bit being placed in the mouth. This will vary depending on the size of wolf tooth removed but may be as long as ten days.



INSTRUMENTS USED FOR WOLF TOOTH REMOVAL

Do Wolf Teeth cause problems?

It is commonly believed that wolf teeth cause problems with some horses when bitted. There are also many horses with wolf teeth that work very effectively and without discomfort. Displaced or sharp wolf teeth can cause pain on the cheeks when pressure is put on by the bit and bridle. Some wolf teeth do become loose, diseased or associated with persistent ulceration, which may cause pain.

X-ray studies of horses with bits in their mouth have shown that the bit sits in the 'bars' in close proximity to the front lower teeth (rather than the upper cheek teeth and wolf teeth). It is therefore unlikely that small wolf teeth that sit immediately in front of the first upper cheek teeth cause any pain or interference with the bit. The decision to remove wolf teeth will depend on many factors such as size, position and reaction to pressure over the wolf teeth. It will also depend on the age of the horse and the behaviour of that animal when worked.

LEAVE WOLF TEETH ALONE IF...

- never ridden or bitted;
- older horse that works well.

REMOVE WOLF TEETH IF...

- young animal before backing;
- blind wolf teeth;
- wolf teeth in lower jaw;
- any doubt as to horse's comfort on the bit;
- wolf teeth are mobile/wobbly.

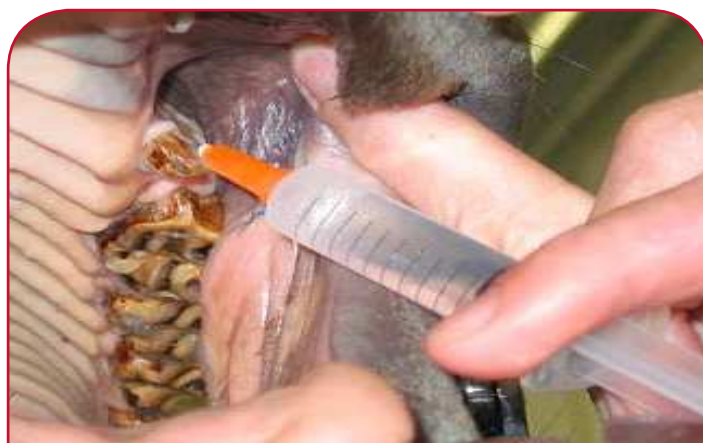If your horse has wolf teeth and you are uncertain whether they should be removed please discuss with your veterinary surgeon.

WHAT ARE THE RISKS OF WOLF TEETH REMOVAL?

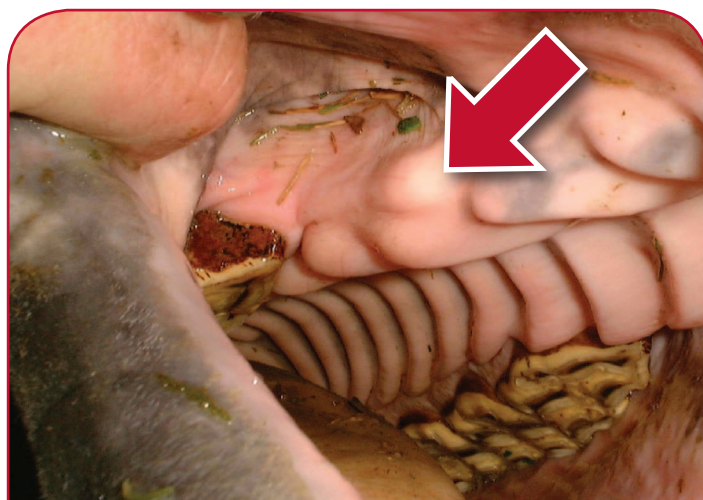
Despite extreme care in removal, some wolf teeth may fracture leaving a fragment of root deep in the gum. These root fragments often don't cause a problem, but at a later date may work loose and appear at the gum surface and may require future extraction.

Adjacent to the wolf teeth is the large palatine artery, damage to which must be avoided!

The risks of root fracture and artery damage can be minimised by effective sedation and local anaesthetic.



LOCAL ANAESTHETIC BEING INJECTED AROUND A WOLF TOOTH



A BLIND WOLF TOOTH



XLVets Equine is a novel and exciting initiative conceived from within the veterinary profession made up of independently owned, progressive veterinary practices located throughout the United Kingdom, members of XLVets Equine are committed to working together for the benefit of all their clients.
© XLVet UK Ltd.

No part of this publication may be reproduced without prior permission of the publisher.

For further information contact your local XLVets Equine practice:



Wright and Morten Veterinary Surgeons
Somerset, Cheshire, 08458 330034
Lower Withington, Cheshire, 08458 330034
www.wmvets.co.uk