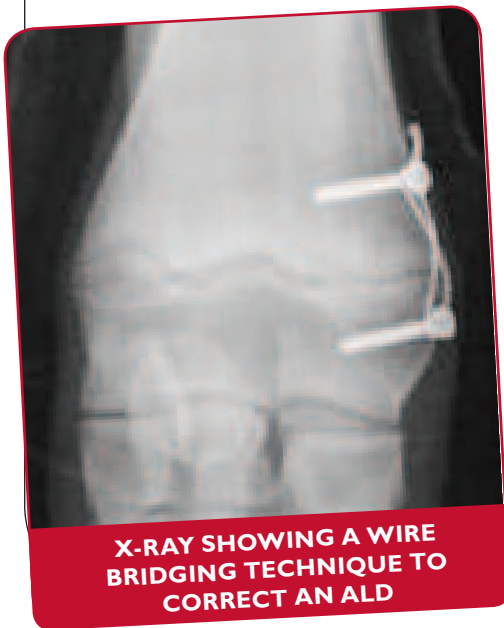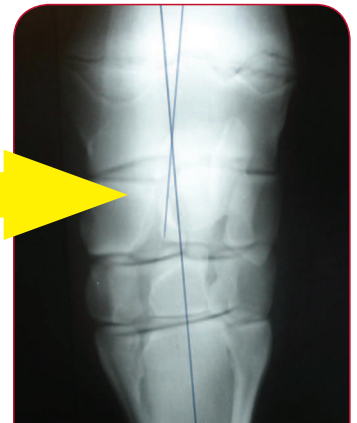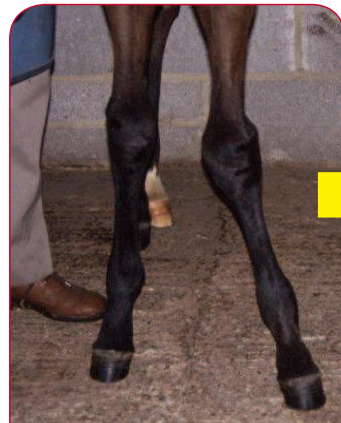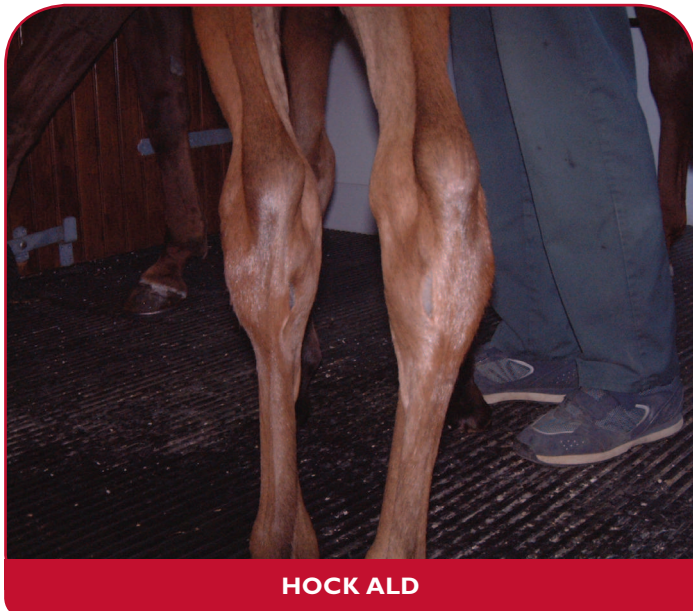


Angular Limb Deformities in Foals



Angular limb deformities (ALDs), often referred to as bent legs, are a relatively common condition, most frequently affecting new born or relatively young, growing foals during the first few months of life. When viewed from in front or behind, the lower limbs either divert towards or away from midline. The knee (carpus), fetlock, and hock are the most frequently affected joints. ALDs usually develop due to a difference in the rate of bone growth across the growth plate adjacent to the affected joint. A growth plate is an area of cartilage within the bone of young animals that is responsible for the increase in bone length as the animal grows.



CAUSES

There are several reasons for the development of an ALD:

- 1 uneven growth across the growth plate;
- 2 poorly calcified bones;
- 3 loose soft tissues around the joint;
- 4 bending along the cannon bone.

ANGULAR LIMB DEFORMITIES

- Can be present at birth or develop as the foal grows.
- Can affect single or multiple limbs and joints.
- Require prompt treatment especially when involving the fetlock joint.
- Are usually treated by remedial foot trimming and glue on shoes.
- May need surgery to speed up or slow down limb growth.

TREATMENT

Many foals are born with mild ALDs that will correct themselves without any treatment other than restricting the size of the turnout area for a few weeks.

ALDs involving the fetlock joints should be assessed and treated promptly as the window of opportunity for effective treatment is narrow, most growth happening before two months of age.

ALDs involving the hock and knee joints should generally be treated before four and six months of age respectively.

Accurate assessment of the degree and exact site of angulation is undertaken using radiography (x-rays).

- Treatment of mild cases involves foot trimming to balance the hoof wall and the application of glue-on shoes with an extension on one side of the foot.
- Regular assessment and trimming is necessary to re-balance the foot and monitor correction of the deformity, which can take a month or two.
- Topical treatment using shockwave therapy has also been shown to aid in the correction of some ALDs.

More severe deformities, or those which occur near the end of the window of maximum growth, may need surgery to correct the problem.

Surgical therapy, under general anaesthesia, can involve a couple of procedures:

1. A periosteal strip: "stripping" stimulates growth on the slow side of the growth plate.
2. Wire bridging: this technique slows down growth on the fast growing side.

Most improvement should occur over the month following surgery.


Bridging surgery requires a second procedure to remove the wire bridge once the limb has straightened.

Following surgery, patients need to be confined to protect the

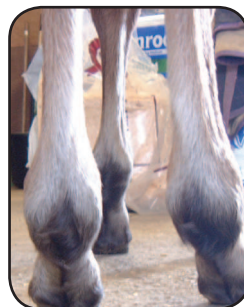
wounds and affected growth plates from trauma. Some limited swelling and scarring may persist at the surgical site(s).

The prognosis for ALDs is generally good if identified and treated promptly within the window of opportunity for the respective joint.

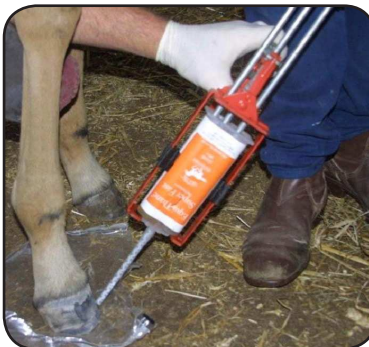BEFORE



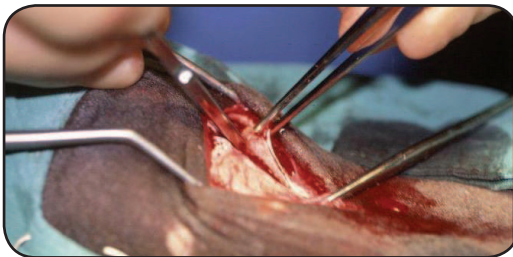
AFTER



**HINDLEG FETLOCK
ALD BEFORE AND
FOUR WEEKS AFTER
TREATMENT WITH A
GLUE ON SHOE**



Applying a hoof extension to correct ALD



**SEPARATING THE
OUTER BONE
MEMBRANE
DURING
PERIOSTEAL
STRIP SURGERY
FOR KNEE ALD**



XLVets Equine is a novel and exciting initiative conceived from within the veterinary profession made up of independently owned, progressive veterinary practices located throughout the United Kingdom, members of XLVets Equine are committed to working together for the benefit of all their clients.

© XLVet UK Ltd.

No part of this publication may be reproduced without prior permission of the publisher.

For further information contact your local XLVets Equine practice:



Wright and Morten Veterinary Surgeons
Somerset, Cheshire, 08458 330034
Lower Withington, Cheshire, 08458 330034
www.wmvets.co.uk